

सेवा में

Giggles Foundation
1516, 2nd Floor Wazir Nagar
Kotla Mubarakpur
New Delhi - 110003

महोदय

मेरा नाम रमेश शंकर कुमार है हम रावठीपुर (वैशाली)
जिला बिहार के रहने वाले है हमारा बेटा का नाम
रेखांश कुमार है वह तीन ~~साल~~ वर्ष का है हमारा
बच्चा को ~~ब्र~~ एलेसर प्रोस्टेट में है हम पिछले एक
साल से यहाँ Feb 2024 से दिल्ली AIIMS अस्पताल
में इलाज करा रहे है डॉक्टर ने बताया है की अभी
हमारे बच्चे की Chemotherapy और यलोजी | Chemotherapy
के बाद CT Scan कराएंगे। उनके बाद बताएंगे
की Surgery है की नहीं है। हमारे इलाज में
बहुत खर्च होगा। हम एक मजदूर है हम अपनी
वस बच्चा का इलाज आगे करी में अलम है
आपले निवेदन है कि हमारा इलाज करी में हमारे
सहायता करे

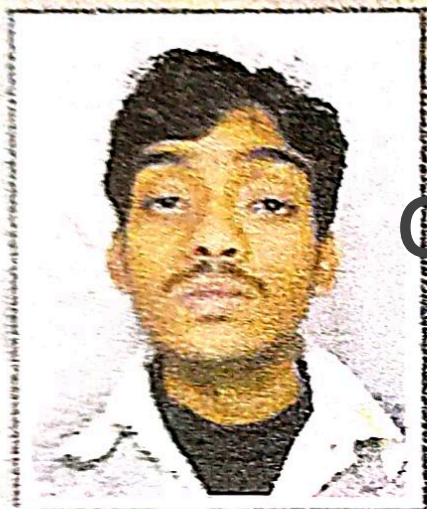
For GIGGLES FOUNDATION
Madhu Kumari
or

समनस

Ravi Shankar 18



भारत सरकार
Government of India



रवि शंकर कुमार

Ravi Shankar Kumar

जन्म तिथि / DOB : 04/01/1994

Giggles Foundation



7067 7529 8828



7667 7529 8828

मेरा आधार, मेरी पहचान




भारतीय विशिष्ट पहचान प्राधिकरण

Unique Identification Authority of India



पता: S/O राम नारायण राय, जुरामंपुर करारी,
वैशाली, बिहार, 844508

Address: S/O Ram Narayan Ray,
Juramanpur Karari, Vaishali, Bihar, 844508



Giggles Foundation

7667 7529 8828



1947



help@uidai.gov.in



www.uidai.gov.in



बिहार सरकार

GOVERNMENT OF BIHAR
योजना और विकास विभाग

DEPARTMENT OF PLANNING AND DEVELOPMENT
प्राथमिक स्वास्थ्य केन्द्र राघोपुर
PRIMARY HEALTH CENTRE RAGHOPUR

फॉर्म-5
FORM-5



जन्म प्रमाण-पत्र
BIRTH CERTIFICATE

सं. 1
NO. 1



(जन्म मृत्यु रजिस्ट्रेशन अधिनियम, 1969 की धारा 12 / 17 तथा बिहार जन्म मृत्यु रजिस्ट्रेशन नियम, 1999 के नियम 8/13 के अन्तर्गत जारी किया गया)
(ISSUED UNDER SECTION 12/17 OF THE REGISTRATION OF BIRTHS & DEATHS ACT, 1969 AND RULE 8/13 OF THE BIHAR REGISTRATION OF BIRTHS & DEATHS RULES 1999)

यह प्रमाणित किया जाता है निम्नलिखित सूचना जन्म के मूल अभिलेख से ली गई है जो कि प्राथमिक स्वास्थ्य केन्द्र राघोपुर तहसील राघोपुर जिला वैशाली राज्य/संघ प्रदेश बिहार, भारत के रजिस्टर में उल्लिखित है।
THIS IS TO CERTIFY THAT THE FOLLOWING INFORMATION HAS BEEN TAKEN FROM THE ORIGINAL RECORD OF BIRTH WHICH IS THE REGISTER FOR PRIMARY HEALTH CENTRE RAGHOPUR OF TAHSIL/BLOCK RAGHOPUR OF DISTRICT VAISHALI OF STATE/UNION TERRITORY BIHAR INDIA.



नाम / NAME: REYANSH KUMAR

लिंग / SEX: पुरुष / MALE

जन्म तिथि / DATE OF BIRTH:

31-08-2021

THIRTY-FIRST-AUGUST-TWO THOUSAND TWENTY ONE

जन्म स्थान / PLACE OF BIRTH:

PRIMARY HEALTH CENTRE RAGHOPUR

माता का नाम / NAME OF MOTHER:

NILU KUMARI

Giggles Foundation

पिता का नाम / NAME OF FATHER:

RAJESH KUMAR

माता का आधार नंबर / MOTHER'S AADHAAR NO:

आधार नंबर / FATHER'S AADHAAR NO:

बच्चे के जन्म के समय माता-पिता का पता / ADDRESS OF PARENTS AT THE TIME OF BIRTH OF THE CHILD:

JURAMANPUR KARARI, RAGHOPUR, VAISHALI, BIHAR

माता-पिता के स्थायी पता / PERMANENT ADDRESS OF PARENTS:

JURAMANPUR KARARI, RAGHOPUR, VAISHALI, BIHAR

पंजीकरण संख्या / REGISTRATION NUMBER:

2024: 10-08588-000957

पंजीकरण तारीख / DATE OF REGISTRATION:

22-02-2024

टिप्पणी / REMARKS (IF ANY):

जारी करने की तिथि / DATE OF ISSUE:

2-02-2024

जारी करने वाला प्राधिकारी / ISSUING AUTHORITY:

रजिस्ट्रार (जन्म एवं मृत्यु)
REGISTRAR (BIRTH & DEATH)

प्राथमिक स्वास्थ्य केन्द्र राघोपुर
PRIMARY HEALTH CENTRE RAGHOPUR

प्रभाषी चिकित्सा पदाधिकारी
प्राथमिक स्वास्थ्य केन्द्र
राघोपुर (वैशाली)

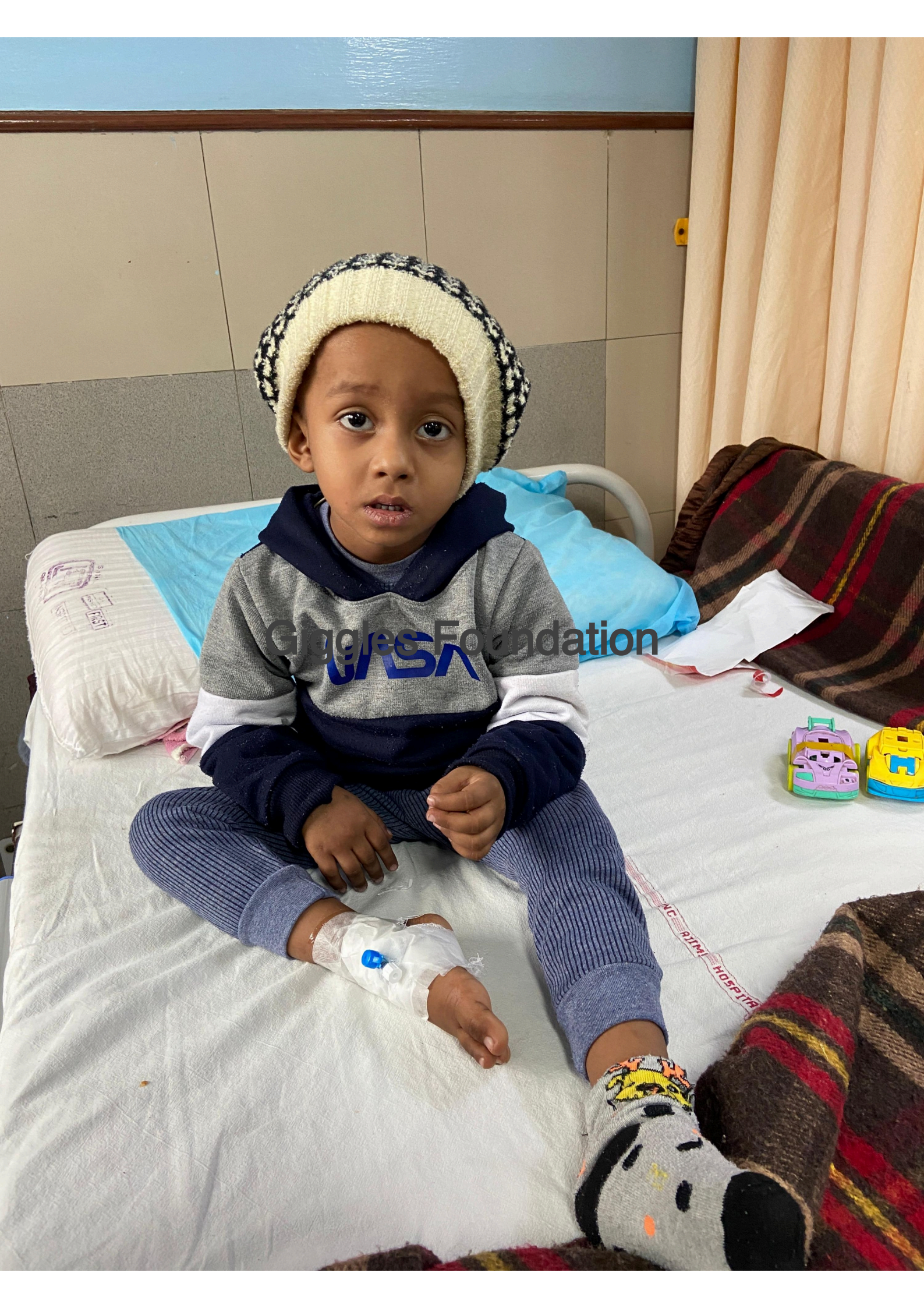परीक्षण किया गया /

2-02-2024 14:17:20



"THIS IS A COMPUTER GENERATED CERTIFICATE."

"THE GOVT. OF INDIA VIDE CIRCULAR NO. 1/12/2014-VS(CRS) DATED 27-JULY-2015 HAS
DECLARED THIS DOCUMENT AS A LEGAL DOCUMENT FOR ALL OFFICIAL PURPOSES."



Giggles Foundation



अखिल भारतीय आयुर्विज्ञान संस्थान, नई दिल्ली
ALL INDIA INSTITUTE OF MEDICAL SCIENCES, NEW DELHI
DEPARTMENT OF PATHOLOGY

Patient Name	: REYANSII KUMAR	UHID NO.	: 107346526
Accession No	: S2408294	F/H Name	:
Age/Sex	: 2Y /Male	Additional ID	: N/A
Clinic/Dept	: Paediatric Surgery	Unit	: N/A
Consultant Incharge	: Not Mentioned	Request Date/Time	: 04-03-2024 /14:56:44
		Receiving Date/Time	: 04-03-2024 /16:18:25

HISTOPATHOLOGY REPORT

MICROSCOPIC EXAMINATION:

Received one paraffin embedded tissue block(s) for review as Biopsy from prostate mass (labeled H-1390/2022 dated 1.2.2022)

Sections examined shows a malignant tumor with round to ovoid cells in a myxoid background .Hypo and hyper cellular areas are noted. The neoplastic cells are diffusely immunopositive for desmin and focally for myogenin.

Impression : Rhabdomyosarcoma, morphologically suggestive of Embryonal Rhabdomyosarcoma.

Note: Fluorescent in situ hybridization for P53 gene fusion is being performed and complementary report will follow.

DIAGNOSIS:

S2408294A

Rhabdomyosarcoma NOS 8900/3

End Report

Reporting Resident: Dr. Shradhanjali Satapathy

Reporting Faculty: Dr. Lavleen Singh

Reporting Date/Time: 13-03-2024 18:0

Disclaimer :

1. This report is electronically generated and does not require a signature or stamp to be considered valid.
2. The pathology diagnosis is to be interpreted by the treating physician in conjunction with clinical features, imaging, and other investigations.



अखिल भारतीय आयुर्विज्ञान संस्थान, नई दिल्ली
ALL INDIA INSTITUTE OF MEDICAL SCIENCES, NEW DELHI
DEPARTMENT OF PATHOLOGY

Patient Name	: REYANSH KUMAR	UHID NO.	: 107346526
Accession No	: S2408294	F/H Name	:
Age/Sex	: 2Y /Male	Additional ID	: N/A
Clinic/Dept	: Paediatric Surgery	Unit	: N/A
Consultant Incharge	: Not Mentioned	Request Date/Time	: 04-03-2024 /14:56:44
		Receiving Date/Time	: 04-03-2024 /16:18:25

HISTOPATHOLOGY REPORT

MICROSCOPIC EXAMINATION:

Received one paraffin embedded tissue block(s) for review as Biopsy from prostate mass (labeled H-1390/2022 dated 1.2.2022).

Sections examined shows a malignant tumor with round to ovoid cells in a myxoid background .Hypo and hyper cellular areas are noted. The neoplastic cells are diffusely immunopositive for desmin and focally for myogenin.

Impression : Rhabdomyosarcoma, morphologically suggestive of Embryonal Rhabdomyosarcoma.

Note: Fluorescent in situ hybridization for FOXO1 fusion is being performed and a supplementary report will follow.

DIAGNOSIS:

S2408294A Block for review

Rhabdomyosarcoma NOS 8900/3

Reporting Resident: Dr. Shradhanjali Satapathy

Reporting Faculty: Dr. Lavleen Singh

Reporting Date/Time: 13-03-2024 18:00

SUPPLEMENTARY REPORT :

Fluorescent in situ hybridization for FOXO1 fusion performed is non contributory owing to scant tumor tissue.

End Report

Reporting Resident: Dr. Yashika Maheshwari

Reporting Faculty: Dr. Lavleen Singh

Reporting Date/Time: 05-04-2024 14:10

Disclaimer :

This report is electronically generated and does not require a signature or stamp to be considered valid.

The pathology diagnosis is to be interpreted by the treating physician in conjunction with clinical features, imaging, and other investigations.



अखिल भारतीय आयुर्विज्ञान संस्थान, नई दिल्ली
ALL INDIA INSTITUTE OF MEDICAL SCIENCES, NEW DELHI
DEPARTMENT OF PATHOLOGY

Patient Name	:	REYANSII KUMAR	UHID NO.	:	107346526
Accession No	:	S2407538	F/H Name	:	
Age/Sex	:	2Y /Male	Additional ID	:	NA
Clinic/Dept	:	Paediatric Surgery	Unit	:	N/A
Consultant Incharge	:	Dr. Vishesh Jain	Request Date/Time	:	29-02-2024 /10:30:01
			Receiving Date/Time	:	29-02-2024 /12:07:17

HISTOPATHOLOGY REPORT

GROSS EXAMINATION:

Accession No. : S2407538A

Received specimen labelled as "bone marrow biopsy"

Received 2 linear bony tissue piece(s) together measuring 0.5-0.6 × 0.1 × 0.1 cm.

MICROSCOPIC EXAMINATION:

Bone marrow biopsy is fragmented with fragment of cartilage, few subcortical marrow elements, procedural hemorrhage and washed out marrow spaces. Scant marrow spaces includes shows trilineage hematopoiesis. There is no evidence of metastasis in the sections examined.

Note : Patient is a known case of Rhabdomyosarcoma - no clinical history.

DIAGNOSIS:

S2407538A	Bone Marrow	Bone marrow biopsy exact site not mentioned	Descriptive, see above
-----------	-------------	---	------------------------

End Report

Reporting Resident: Dr. Shradhanjali Satapathy

Reporting Faculty: Dr. Lavleen Singh

Reporting Date/Time: 06-03-2024 11:38

Disclaimer :

1. This report is electronically generated and does not require a signature or stamp to be considered valid.
2. The pathology diagnosis is to be interpreted by the treating physician in conjunction with clinical features, imaging, and other investigations.



Department of Nuclear Medicine and PET-CT
All India Institute of Medical Sciences
New Delhi, India

Patient Name: REYANSH KUMAR		Age/Sex: 2Y/M
Study ID: MDP-47-20670-24	UHID: 107346526	Date: 27.03.2024

Indication: prostatic rhabdomyosarcoma for metastatic work-up.

^{99m}Tc - MDP WHOLE BODY BONE SCAN

Findings:

- *Physiological radiotracer accumulation noted in the growth plates.*
- Normal radiotracer distribution noted throughout the skeleton.
- Bilateral kidneys are visualized.

IMPRESSION:

➤ No definite evidence of osseous metastatic disease.

(Bone scan has low sensitivity for purely lytic lesions)

Senior Resident

Consultant



PATIENT'S NAME: REYANSH KUMAR	AGE/SEX: 2.5 YRS/ MALE
REF. BY: AIIMS HOSPITAL	M24Z28-0024320
EXAM. DATE: 28-02-2024	

CECT SCAN - CHEST

PROCEDURE

Volumetric scanning of chest region was done using 128 slices MDCT scanner before and after intra-venous administration of non-ionic iodinated contrast media. The patient was observed for adverse contrast reactions for time frame of 30 minutes. Procedure was uneventful. No adverse contrast reaction noted. The images were evaluated in appropriate window settings.

FINDINGS:

Evidence of paratracheal, right hilar, left paraaortic, subcarinal enhancing lymphnodes are noted largest measuring 12.3x9.6 mm in pretracheal region.

Lung parenchyma reveal normal broncho-vascular markings. No obvious focal lung lesion seen.

Trachea is normal in position.

Cardium and mediastinal great vessels are normal.

There is no evidence of pericardial or pleural effusion.

Visualized bones are unremarkable.

OPINION: CT findings reveal

- Dr. • Subcentimetric sized mediastinal lymphadenopathy as described (insignificant).

Please correlate clinically.

DR NEHA SINGH
CONSULTANT RADIOLOGIST
DMRD DNB RADIODIAGNOSIS
DMC-42756

Not valid for medico-legal purpose

This is only radiological professional opinion and not a final diagnosis. X-ray, USG, CT/ MRI also has its limitations. Therefore, X-ray, USG, CT/ MRI report should be interpreted in correlation with clinical and pathological findings.



RADIOLOGY UNIT

Dr. B. R. Ambedkar Institute Rotary Cancer Hospital
All India Institute of Medical Science, New Delhi -110029

Patient Name	REYANSH KUMAR	Gender/Age	M/2 y
UHID	107346526	Exam Date	04/06/2024 11:06AM
OPD / Ward:	Paediatric Surgery-IRCH	Modality	CT
Procedure Name	IRCH CT Chest, Abdomen, Pelvis		

Procedure: CECT of Chest, Abdomen & Pelvis.

Clinical background: Case of BP RMS - post treatment.

Chest

Both lungs: Normal, No focal lesion.

Mediastinum: Normal, No lymph node enlargement.

Trachea, main bronchi: Normal.

No pleural or pericardial effusion.

Abdomen & Pelvis

Giggles Foundation

An irregular, heterogeneously enhancing mass measuring ~ 5.1 x 1.9 x 3.2cms in the extraperitoneal pelvis in the rectovesical space, with lower extending upto right ischioanal fossa. Anteriorly, loss of fat plane with posterior wall of UB and posteriorly with anterior wall of lower rectum and anal canal (though no infiltration of UB or rectum is seen). Laterally, loss of fat plane with right obturator muscle.

Liver: Normal. No focal lesion.

CBD/ Gall bladder: Normal.

Pancreas: Normal.

Spleen: Normal.

Both kidneys/ ureters: Normal, No hydronephrosis.

Retroperitoneum/ vessels: Normal. No lymph node enlargement.

Free fluid: No ascites.

Urinary bladder: Normal.

Additional information: None.

Comparison: As per previous scan dated 25/01/2024, there is significant decrease in the size of the mass (absolute measurement not possible as scale not provided)

Impression: In a K/c/o BP RMS, present scan reveals:

- Irregular, heterogeneously enhancing mass in the extraperitoneal pelvis in the rectovesical space, with lower extent upto right ischioanal fossa and relations as mentioned.

Preliminary hv: Dr. Mohammed Chettiartodl (Junior Resident). 04-Jun-2024 15:41



डॉ. बी. आर. अम्बेडकर संस्थान रोटरी कैंसर अस्पताल
Dr. B.R. Ambedkar Institute Rotary Cancer Hospital
A.I.I.M.S. Hospital

Out Patient Department
G PROHIBITED IN HOSPITAL PREMISES

OPF

DR. B.R.A. IRCH, AIIMS, NEW DELHI

IRCH No. 314733

Clinic Paed Surgery Clinic

Deptt. PAEDIATRIC SURGERY-IRCH
General

Reg. Date-29/02/2024

Clinic No. 2024/4399



UHID-107346526

नाम

Name REYANSII KUMAR

S/O- RAVI SHANKAR KUMAR

Phone No. 9801557800

Address JURAWANPUR KARARI RAGHO PUR DIST VAISHALI, BIHAR,
Pin-0, INDIA

Sex/Age M/2Y

Room 6 (Shift Afternoon)

ब०रो०वि० पंजीकृत सं०/O.P.D. Regn. No.

पुत्री of	लिंग Sex	आयु Age	जन्म तिथि/Date of Birth

निदान/ Diagnosis

Dr Rme

दिनांक/Date

उपचार/ Treatment

11/7/24

course 6 wa (16)

Adv. - inj adinonycin 0.5mg x 2

- inj vincristine 1mg x 1

Giggles Foundation

- inj cytarabine 500mg x 1

- inj melna 200mg x 4

hxr RW

mcn (6) ward

18/7/24

8/8/24

Adv.

→ Inj Vincristine . 0.8mg

→ IV - 29/8/24

22 AUG 2024

CT
8/8/24

अंगदान-जीवन का बहुमूल्य उपहार / ORGAN DONATION - A GIFT OF LIFE

O.R.B.O.AIIMS, 26588360, 26593444, www.orbo.org Helpline-1060 (24 hrs. service)

बाहर से आने वाले रोगियों के लिए धर्मशाला की सुविधा उपलब्ध है/ Dharamshala facility is available for outstation patient

111

Due for week 8 Unmo

Ad V.

① 21w on 16/5/24 to CB2

⑦ Dr. VINCRISTINE

0.8 mg Ev

9/5/24

Unk'd

1. Exp. literature - In

- Inj. Cyclophosphamide

Trj. Mexico - 1991 - 1992

→ Now asymptotic:-

Giggles! Foundation

- currently having $T_{\text{fore}} = 102^\circ\text{F}$ \rightarrow Good and T_{feet} in
 - $T_{\text{fore}} = 102^\circ\text{F}$ \rightarrow previous week
 - CAC (15/5/24) :- 11.4 / 4300 / ANC - 1.16

Chow de Aguarda

- CWK q VAC chemo

- Revision 31/5/24 Ques

- Revision on 21/5/24

9 AM to 12 PM SPA

Chlorophyll α and β

— 12 —

Carbido

25/4/14

15. *Belinomyces* 2-500m (2)

- D₁ Vorlesung - 19^V - ①

- 30 Cyclophorus - 500

金安大司馬 9.4.20.24. 18. 18. 18. 18. 18.



~~Dr. B.R. Ambedkar Institute Rotary Cancer Hospital~~ ~~3/7/24~~ ~~RedS=~~
 डॉ. बी. आर. अम्बेडकर संस्थान रोटरी कैंसर अस्पताल
 Dr. B.R. Ambedkar Institute Rotary Cancer Hospital
 r/A.I.I.M.S. Hospital
 Out Patient Department
 IG PROHIBITED IN HOSPITAL PREMISES

OFF
RT- 12850

DR. B.R.A. IRCH/AIIMS, NEW DELHI

IRCH No. 314733
 Child Paed Surgery Clinic
 Deptt. PAEDIATRIC SURGERY-IRCH
 General

Reg. Date-29/02/2024
 Child No. 2024/A399



UHID-107346526

नाम
 Name REYANSH KUMAR
 S/O- RAVI SHANKAR KUMAR
 Phone No. 9801557800
 Address: BURAWHIPUR KARARI RAGHO PUR DIST VARSHALI, BIHAR,
 Pin-9, INDIA

RedS

Sex/Age M/2Y
 Room 6 (Shift Afternoon)

दस्तावेज पंजीकृत सं/O.P.D. Regn. No.

पुत्री of	लिंग Sex	आयु Age	जन्म तिथि / Date of Birth
			<i>RedS</i>

निदान / Diagnosis

BP-RMS

दिनांक / Date

उपचार / Treatment

30/05/24

CRW - R y. Dmg
Advice


week 10 chemotherapy

CAN RSD

Giggles Foundation

2mg VCR
1mg/1mg
02M

trial - Exp. Emetet (2mg/5ml) 1-2.5ml SOS.



Date: Time: 7:30 AM

05/11/2024
3

5/6/24

RT ward IRCH, 1st floor
Dr. Arvin

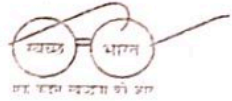
अंगदान-जीवन का बहुमूल्य उपहार / ORGAN DONATION - A GIFT OF LIFE
 O.R.B.O.AIIMS, 26588360, 26593444, www.orbo.org Helpline-1060 (24 hrs. service)

बाहर से आने वाले रोगियों के लिए धर्मशाला की सुविधा उपलब्ध है / Dharamshala facility is available for outstation patient

Register Dr. A. Bonas - 5/3/44
Columb. I.



क्र. 87293. S2408294
 ओ भा० आ० सो अस्पताल / A.I.I.M.S. HOSPITAL
 बहिरंग रोगी विभाग / Out Patient Department
 अस्पताल के अंदर धूम्रपान मना है / SMOKING IS PROHIBITED IN HOSPITAL PREMISES



बाल शल्यचिकित्सा

कमरा / Room



UHID: 107346526
 ABHA: 0

G-31
 Unit-I

Dept No.: 20240220001126

Paediatric Surgery OPD

नं. रोगी पंजीकृत / O.P.D. Regn. No.

आयु
 Age

पता / Address

REYANSH KUMAR

गैंगल

27/02/2024

SORAVI SHANKAR KUMAR

Queue: N21

2Y 5M 27D / M (पुरुष)

Add: JURAWANPUR KABASI RAGHO PUR DIST

VAISHALI, BHUPAL, PIN-8, INDIA

Mobile: 9801557800 New Patient Gender: M

9801557800

निदान / Diagnosis

BP-RMX

दिनांक / Date

उपचार / Treatment

(12)

Wt - 88 cm

Giggles Foundation

27/02/24

IRCA, Room No. 6.

DOB- 31/8/2021

clb poor urinary stream
 straining during
 micturition } x1m
 urinary dribbling
 & hematuria
 & pyuria / month
 black.
 h/o cat urinary retention
 & catheterisation 1 month b
 h/o straining during
 defecation also
 no h/o fever / abdominal
 lump / FTT.

Initially evaluated
 at AIIMS Patna

OTT

413129
 Dr. Pranjali
 64 months
 For hematuria
 HPE from Jaipur

Full
 Pgms

O/E - G (free). Vitals stable
 P/A - soft RT. No amp palpable
 L/E - phallus (2)
 P/R - Extraluminal mass present
 on abd. abutting anterior
 wall of rectum - 1cm above
 anal ring. not possible
 to reach upper border.
 no fecal mass.

Chest } unv.
 CVS

12/3/24

Poley's catheter
 changed



CLEAN AND GREEN AIIMS / एम्स का यही संकल्प, स्वच्छता से काया कल्प

अंगदान जीवन का बहुमूल्य उपहार / ORGAN DONATION - A GIFT OF LIFE

O.R.B.O., AIIMS, 26588360, 26593444, www.orbo.org Helpline - 1060 (24 hrs service)

meraaspatal.nhp.gov.in

IX.

USG WIA (25/01/24) - Hypoechoic mass 3.4x3.79x3.42cm near parastatic area.

C7 ~~ADP~~ ADP (26/01/24) - prostate gland, 5.3x4x4.3cm intracapsular area projecting into bladder lumen. Posteriorly, abutting rectum & effacing fat planes. Inferiorly, extending into levator ani muscle. B/L VJ not involved. infiltrating (R) intraurethral. Indistinct borders. No HDM. No & posterior wall of UB.

HPE (11/02/24) (AIIMS, Patna) (Pnd, - 610 RMS (true for Desm.) & myo D1).

img (22/01/24) - 13.1/10, 310/256K.

RFT (27/01/24) - 17/014/140/45

LFT (29/01/24) - WNL.



CIDW Dr V. Jatin

Giggles Foundation

Advice

- CECT chest
- Bone scan - 27/3/24
- Skeletal survey -
- Bone marrow aspirate and biopsy.
- Biopsy hemline at AIIMS, New Delhi

Salah's Needle

MCH 6B
Needle,
Dr Koushal,
T66, Salah
Needle.

Father wants to
continue T
Rx at
AIIMS, Delhi.

Long course of Rx / logistic issues at AIIMS, New Delhi / prognosis of disease explained to father. Thursday, 2PM, Room No 6 (Dr. Jatin).

IRCH Registration - (29/2/24)

DTAC

SR

Submit films
in 4-39

C fresh Hmg / KFT / LFT

Please to come on 28/2/24 & needle biopsy

To come on
11/3/24
@ 10am



डॉ. बी. आर. अम्बेडकर संस्थान रोटरी कैंसर अस्पताल Dr. B.R. Ambedkar Institute Rotary Cancer Hospital

'A.I.I.M.S. Hospital

at Patient Department

OPR

DR. B.R.A. IRCH, AIIMS, NEW DELHI

IRCH No. 314733

Reg. Date-29/02/2024

Clinic Paed Surgery Clinic

Clinic No. 2024/4399

Deptt. PAEDIATRIC SURGERY-IRCH

General



UHID-107346526

ब०रो०वि० पं०कृत सं०/O.P.D. Regn. No.

नाम

Name REYANSH KUMAR

S/O- RAVI SHANKAR KUMAR

Phone No. 9801557800

Sex/Age M/2Y

Address JURAWANPUR KARARI RAGHO PUR DIST VAISHALI, BIHAR,

Pin-0, INDIA

Paid Online

पुत्री of	लिंग Sex	आयु Age	जन्म तिथि / Date of Birth

निदान / Diagnosis

BPRMS

दिनांक / Date

21/3/24

उपचार / Treatment

cldw on. Vishesh Jan

Adh

my vironis hie 0.8mg a start Cwk 2
- ci date for 1st wk Jan

i Arch. Hgm for

Giggles Foundation

syf Emaset 2ml 50s

SELPS

28/3/24

W/C/O BP-AMS.

wt = 10.5 kg
ht = 87 cm.

On VAC chemotherapy.

Received week 2 chemo

Inj VCR on 21/3/24

12.1 > 13530 < 2.23 loc.
85 64

DD,
The Dharamshala,

kindly provide accommodation

अंगदान-जीवन का बहुमूल्य उपहार / ORGAN DONATION - A GIFT OF LIFE

O.R.B.O. AIIMS, 26588360, 26593444, www.orbo.org Helpline-1060 (24 hrs. service)

बाहर से आने वाले रोगियों के लिए धर्मशाला की सुविधा उपलब्ध है / Dharamshala facility is available for outstation patient

4/0/w Dr. Narayan Prasad

Adv

to ward ↓ Dr. Ram

Week 3 chemo.

Inj Vincristine = 0.6 mg ~~per~~

Inj Actinomycin = 661 mg.

Inj cyclophosphamide = 588 mg.

Inj MESNA 245 mg.

Continue Vitcofol

Continue Syt A-Z.

CBC.

R/v for week 4 chemo. on 4/4/24 IRCH
Room 6 # 2 pm c c c.

4/4/24

BP-RN

Giggles Foundation

Smiley

Adv.

① Inj. CDistine. 0.7 mg 2v.

CT 4/4/24

② R/v on 18/4/24

③ Syt. Sine rest.

Adv 4/4/24

3.5 ml BD x 5 days

18/4/24

- Due for wt 5 → At room 15

CT 18/4/24

Adv 1 Inj. VCR 0.7 mg. IV bolus

① Steam inhalation BID

② Flu on 25/4/24 c CBC

③ KAC clearance → 60

Adv

26/4/24

Actinomycin D - 0.5 mg - ②

Inj Cyclophosphamide 500mg - ②

Adv

Dr. Ram Sharan

Senior Resident

Department of Pediatrics Surgery

1st Floor, 29/A, 11th St, New Delhi 110029



-AL

OPR-1

EMISES

DR. R.R.A. IRCHLAIMS, NEW DELHI

1984 No. 218722

Reg. Date-29/02/2024

Click **Yes** **Support Clinic**

Case No. 2024-04109

Dept. PAEDIATRIC SURGERY-IRCH
(General)



n. No.

जन्म तिथि/Date of Birth

संस्कृत

UHD-107346526

Name REYANSHI KUMAR

SRI. RAVI SHANKAR KUMAR

Sex/Age M/2Y

Figure 10. 02/10/2014 7:50:30

Room 6 (Shift Afternoon)

Address: SURAWANTPUR KARARI RAGHO PUR DIST. VAISHALI, BIHAR,
Pin- 824201

25-01 2000 1

History/Diagnosis

Bp-AMS

Page 10 of 10

उपचार/Treatment

CLW Prof S Aggarwala / DL & Jani

→ start VAC chemotherapy \equiv week 0, MCH 6
marc CDR can

→ Giggles Foundation
→ get skeletal survey / Bone scan done
as data.

→ collect lion mallow exhibit & Bx
report from Peds & O P D counter
after lunch

⇒ Exp A to 2 2.5ml OD
Exp Valcofol 2.5ml OD
Exp Reptan 2.5ml on alternate days

Ляна
52000

Wm H. D., kindly friend.

inj VLR $1.52 \text{ g/m}^2 \equiv 0.76 \text{ mg/kg}$

Ing Aktivierung in 13 Sept/akt = 0.65 mg

$$2 \text{ mg cyclosporin} / \text{m}^2 + 29 / \text{m}^2 = 0.61 \text{ mm}$$

2) $m = 500 \text{ g}$ 25 cm

$$|_{\text{out}} = 11 \text{ kg}$$

ht = 88 cm

$$BSR = 0.25 \text{ g/m}^2$$

CANKEES
Kindly return

12. Konstanten
17.11.1941 —

Q. 2. By cyclophosphamide - ⑦

ORGAN DONATION - A GIFT OF LIFE

O.R.B.O., AIMS, 26000100, 26001444, www.orbo.org, helpline - 1000 (24 hrs service)

संयुक्त की आगे आगे स्थिति के लिए, संयुक्त की स्थिति का, E/Dnacamanam facility is existing for outstation pattern

③ - 2g Actinomycin D 150 units - ⑦

4. 2g MEGNA 200mg - (5)

~~Q22~~ Rsp A to 2 - ①

~~27~~ V7 TC OFOL

○ Syg sektion - (T)

23/9/2004

[Handwritten signature]

Advice

Giggles Foundation

Advice

Giggles Foundation

→ week 1: 10 mg in stat (Cassim)

→ continue exp A to 2 / Vitecol / section

→ continue off H₂O
→ similar - 14/3/24, 2pm E fresh Hing & lime R.
at 40m.

→ Block members at Allms.

CANKIDS

CANEIDS
kindly issue

ly issue
Vincristine 1 mg/ml

14/3/24

Idus

dalam m. Gali raya.

- chem ok 2 deferred

- hyp septum time not 7 days

- syp PCM 2.5 ml QID x 2 days, then 105

- 1 up RANTRC zone ASD & 7 days

- Review in IRON clinic on 11/3/21 at 2pm on the
to finish case report. *[Signature]*

C.C-080324123 107346526

U.S.-080324027 107346526

RE 7470-00000000



अखिल भारतीय आयुर्विज्ञान संस्थान, नई दिल्ली-110029
ALL INDIA INSTITUTE OF MEDICAL SCIENCES, NEW DELHI -110029
आपातकालीन विभाग

(REVISIT)

(DEPT. OF EMERGENCY MEDICINE)



UHID No:107346526

आपातकालीन नं. (Emergency No): 2024/030/0039823

दिनांक DATE: 29/04/2024

समय TIME: 04:46:54 PM

NON-MLC

नाम NAME: MR. REYANSH KUMAR

आयु AGE: 2 years 7 months 29 days

लिंग /SEX: M

S/O: RAVI SHANKAR KUMAR

पता ADDRESS:

घर/मकान H.NO:

शहर/अंचल CITY/BLOCK:

राज्य STATE:

मोबाइल MOBILE NO:

JURAWANPUR KARARI RAGHO
PUR DIST VAISHALI

BIHAR

9801557800

गली / गुरुद्वारा STREET/MOHI:

पिन PIN:

दवागृह सं. PHONE NO:

स्थान Location:

0

Paediatrics Emergency

कैसे BROUGHT BY: Relative:

Criticality: Red / Yellow / Green

Triage: Responsive/ Unresponsive HR /min BP mmHg RR /min spO2 %

Shifted to Paeds/ Main/ New Emergency

Presenting Complaints

↓ pediatric surgery

Bladder - prostate rhabdomyosarcoma

90 Fever x 1 day

3 week 6 VAC chemotherapy

cough x 1 day

Primary Assessment (ABCDE): As assessed on 29/04/24

Giggles Foundation

Airway Open & stable: Yes/No If No..... Breathing: RR 40/min Efforts: Normal/Poor/increased Auscultation: Air entry: Normal/poor/Differential Added sounds: None/Stridor/Wheeze/Crackles SpO2 on Room air 95%	Circulation HR 120/min CFT 2 secs. BP.....mmHg Peripheral pulse: Poor/Good Central pulse: Poor/Good Skin temp: Warm/cool Others	Disability GCS 15/15 Pupil size...../min Pupillary Reactions..... Motor activity: Normal & Symmetrical/Asymmetrical/ Posturing/Flaccidity/Seizure Blood Sugar:mg/dl Exposure: Temp..... Colour: Normal/pallor/cyanosis /mottled Any other skin lesions.....
--	---	---

Diagnosis

Bladder - prostate rhabdomyosarcoma to 90 FN

WT= 11

100.

100mg Paracetamol 100mg IV SOS

100mg Neb. 2 salbutamol 0.5ml + 3ml NS 3 times

W/4 y Inj. Amikani 150 mg IV OD
To

29/11/2019 - C/S/B SR policy may

cfu for cough. X low grade.

no vomity

cfu BP Ring

on VTE.
Lacton 26/11/2019
(week 6)

→ act for

Giggles Foundation

→ nasal discharge G

CBL
11.3) BK | 223

7.34 | 31
4003 522

Δ ORI
290

Adm

No active infection
for 2 at present

CR - JRT lower
inter infected

Doctor on Duty
Dept. of Emergency Medicine
Allison New

Syp - Acetaminophen (200mg)
Steam Inhalation
MIXT - 3mls
Syrup - 1ml



अखिल भारतीय आयुर्विज्ञान संस्थान, नई दिल्ली-110029
ALL INDIA INSTITUTE OF MEDICAL SCIENCES, NEW DELHI -110029
आपातकालीन विभाग

(REVISIT)

(DEPT. OF EMERGENCY MEDICINE)

118



UHID No:107346526

आपातकालीन नं. (Emergency No): 2024/030/0053743

दिनांक DATE: 03/06/2024

समय TIME: 10:02:00 AM

NON-MLC

नाम NAME: MR. REYANSH KUMAR

आयु AGE: 2 years 9 months 3 days

लिंग /SEX: M

S/O: RAVI SHANKAR KUMAR

पता ADDRESS:

मकान संख्या H.NO:

JURAWANPUR KARARI RAGHO
PUR DIST VAISHALI

गली / गुरुद्वारा STREET/MOHI:

शहर/प्रखंड CITY/BLOCK:

पिन PIN:

0

राज्य STATE:

BIHAR

दूरभाष नं. PHONE NO:

मोबाइल MOBILE NO:

9801557800

स्थान Location:

Paediatrics Emergency

बrought BY: Relative

Criticality: Red / Yellow / Green

Triage: Responsive/
Unresponsive

HR

/min

BP

mmHg RR

/min

spO2

%

Shifted to Paeds/ Main/ New Emergency

BP- RMS

Presenting Complaints

c/o fever x 4 days (99-100° F.)
no c/o cough/cold / loose stool /
vomiting

Primary Assessment (ABCDE) : Assessment Pentagon

Airway Open & stable : Yes/No If No..... Breathing: RR 30/min Efforts: Normal/Poor/increased Auscultation: Air entry: Normal/poor/Differential Added sounds: None/Stridor/Wheeze/Crackles SpO2 on Room air 98%	Circulation HR 98/min CFT 2 sec. BP 98/56 mmHg Peripheral pulse: Poor/Good Central pulse: Poor/Good Skin temp: Warm/cool Others	Disability GCS 15/15 Pupil size...../min Pupillary Reactions..... Motor activity: Normal & Symmetrical/Asymmetrical/ Posturing/Flaccidity/Seizure Blood Sugar.....mg/dl Exposure: Temp..... Colour: Normal/pallor/cyanosis /mottled Any other skin lesions.....
---	---	---

Diagnosis

- ~~Excep~~ last CT (CVCR on 30/5/24)
(CYC 16/5/24)

Adv
CBC - sent
5800
2830
2.53lac

Adv
84p PCM (1/125) 6.5ml 50p
- flu in mid onco OPD

11kg

7157
NCS-68/157

7153 (7157)

एम.आर.-9
M.R.-9

अखिल भारतीय आयुर्विज्ञान संस्थान, नई दिल्ली-110029
All India Institute of Medical Sciences, New Delhi-110029
परामर्श अभिलेख / CONSULTATION RECORD

नाम Name	राजेश Rajesh	आयु Age	299m	लिंग Sex	M	वैवाहिक स्थिति Marital Status	ग. एच.आई.डी. सं. UHD No.
सेवा Service	पार्थिव Parthiv	वार्ड Ward	17N6B	विस्तर Bed	19	व्यवसाय Occupation	धर्म 1023465 Religion स्थिति Status

Referred by Dr.

to Dr.

Requesting Doctor

Consultant & Specialty

Findings :

Date :

Dear Collye

CRD is a do blood - post Pub RMS

on VA ... K ... consider do pt for

Ref: 10/10/24

Diagnosis or Impression :

Toy
SR Parthiv

7204

Recommendations:

etc. referred

Consultant's Signature

4/6/24 - To visit RT OPD on 18/6/24 for heart
RT OPD date


su/ro

Giggles Foundation